



Penile fracture: A rare case of simultaneous rupture of the one *corpus cavernosum* and complete urethral rupture

Fraktura penisa: redak slučaj istovremene ruptуре jednog korpusa kavernožuma i kompletne ruptуре uretre

Djordje Nale*, Nebojša Bojanić*†, Predrag Nikić*

*Clinic of Urology, Clinical Center of Serbia, Belgrade; †Faculty of Medicine, University of Belgrade, Belgrade, Serbia

Abstract

Introduction. Penile fracture is a traumatic rupture of *tunica albuginea* and the tumescent *corpora cavernosa* due to the nonphysiological bending of the penile shaft, presenting with or without rupture of *corpus spongiosum* and urethra. The incidence of concomitant injury of the urethra is 0–38%. Complete urethral rupture is rare, but it is almost always associated with bilateral corporeal injury. **Case report.** We presented a patient with complete urethral rupture, and rupture of the right cavernous body. According to the available literature, this case is extremely rare. **Conclusion.** Fracture of the penis is relatively uncommon and is considered a urologic emergency. Prompt surgical exploration and repair can preserve erectile and voiding function.

Key words:

penis; coitus; wounds and injuries; urologic surgical procedures.

Apstrakt

Uvod. Fraktura penisa je traumatska ruptura tunike albugineje i tumescentnih kavernožnih tela zbog nefiziološkog savijanja tela penisa, sa ili bez ruptуре spongioznog tela i uretre. Učestalost konkomitantne povrede uretre je 0–38%. Kompletna uretralna ruptura je retka, ali je skoro uvek udružena sa bilateralnom korporalnom povredom. **Prikaz slučaja.** Prikazali smo i bolesnika sa kompletnom rupturom uretre i rupturom desnog kavernožnog tela. Prema raspoloživoj literaturi, ovo je izuzetno retka pojava. **Zaključak.** Fraktura penisa je retka, ali se smatra hitnom urološkom povredom. Blagovremena hirurška eksploracija i rekonstrukcija mogu da sačuvaju erektilnu funkciju i funkciju voljnog mokrenja.

Ključne reči:

polni organi, muški; polni odnos; povrede; hirurgija, urološka, procedure.

Introduction

Penile fracture belongs to the group of blunt injuries of the penis. The reason for so rare incidence of penile injuries is the mobility of the penis and its topography. Topographically, the penis is well-protected organ. Penile fracture is unusual, but not rare¹. In erectile condition, the penis is much more vulnerable to injury due to high intracavernous pressure during erection^{1–3}. Traumatic rupture of the *corpus cavernosum* or penile fracture occurs as the consequence of direct blunt trauma of the erectile or semi-erectile penis. Rupture is caused by overextension of *t. albuginea* induced by abrupt increase of intracorporeal pressure². *T. albuginea* tissue is physiologically thinnest in erection, i.e. about 0.25–0.5 mm^{3,4}. In flaccid penis, the thickness of *t. albuginea* ranges from 2 to 3 mm depending upon the region of measurement⁴. The most frequent cause of penile fracture is sexual intercourse, although it may happen during masturbation, manipulation or any other situation of blunt force action^{1,5}.

The exact incidence of penile fracture is not known, because many cases remain unrecorded or many patients do not present to doctor's office because of shame and feeling uncomfortable.

Most cases of penile fracture are without urethral injury and voiding difficulties. Occasionally, due to the effect of mass of edematous tissue and hematoma, the compression of urethra and difficulty with miction may occur. Concurrent urethral injury is present in 0–38% of cases^{2,6}. Complete urethral rupture is rare, but it is almost always associated with bilateral corporeal injury⁶. The presented case showed complete rupture of the urethra, and rupture of the right cavernous body.

Case report

A presented patient was 32 years old. The injury occurred during sexual intercourse in classical position when his spouse was lying on her back with her legs pushed apart

and bent knees, and he was on top. During sexual intercourse, the penis slipped out from the vagina and the patient tried again forced penetration (“he wanted to reenter with all his efforts”), but in misdirection and his penis hit against the pubic symphysis. He heard “as something cracked”, had severe pain and sudden loss of erection. Next, the penis became swollen and blue. He noticed the blood at the meatus. He got scared and immediately presented to emergency urological outpatient department. The patient did not have desire to void. Severe pain aggravated by trying to void, but he could not void.

Physical examination revealed a large hematoma involving the whole penis and angulation of the penis to the left (Figure 1). Diffuse painless hematoma most prominent on the right lateral side and at the base could be palpated. In this area, hematoma appeared as soft, elastic tumefaction, painful and in size of big strawberry. Upon deeper palpation, soft and extremely painful defect was detected in *t. albuginea*. During physical examination, there was no blood at the meatus.

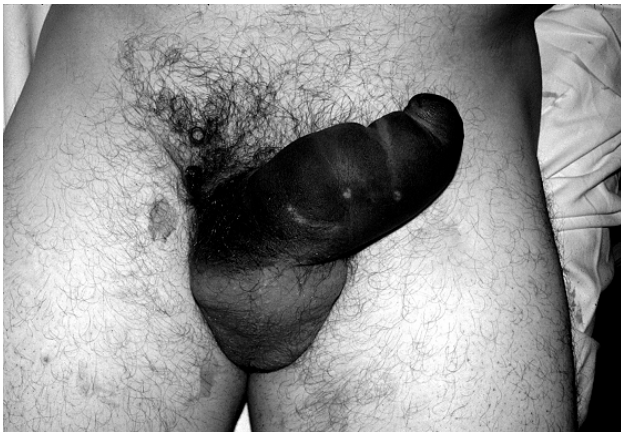

Fig. 1 – Presentation of dexter penile fracture with large edema and hematoma of the penile body. The penis angulates to the opposite side of the site of injury.

Using the straight 7.5 MHz probe, ultrasonographic examination was detected anechogenic change on the right side of the *corpus cavernosum*. Low pressure retrograde urethrogram showed complete disruption at the proximal third of the urethra. Cavrosography was performed using 50% non-ionic contrast and showed the location of extravasation of contrast and the site of rupture of *t. albuginea* on the right lateral base of the penis. In the same area, a large hematoma filled with contrast was visible (Figure 2).

The surgical approach was through peripenile longitudinal anterior incision on the side of hematoma (rupture). After evacuation of hematoma, the laceration of *t. albuginea* was reached, with vital cavernous tissue underneath. *T. albuginea* rupture was transversal in relation to longitudinal axis of the penis with distinct edges (Figure 3).

On the same location, the complete rupture of penile urethra, transversal one with “worn-out” edges could be seen (Figure 4). *T. albuginea* was sutured with 3-0 Vicryl using continuous suture while primary anastomosis of the urethra

was performed *via* catheter using PDS 5-0 interrupted suture with previous urethral spatulation. The operation was completed by vacuum drainage. A broad spectrum antibiotic and low molecular heparin were given during the hospital stay. On the day 12 the catheter was removed.

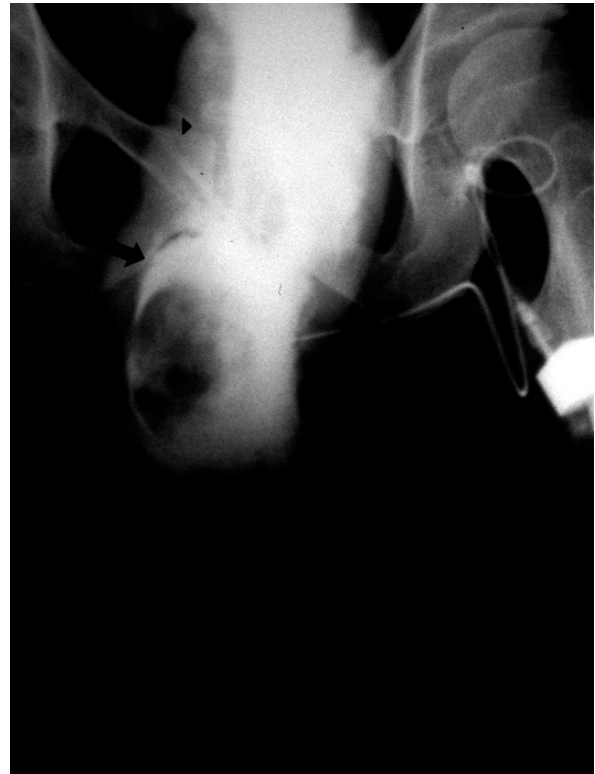

Fig. 2 – Preoperative cavernosography: Hematoma filled with contrast visualized at the right base side of the penis on the site of rupture (black arrows).

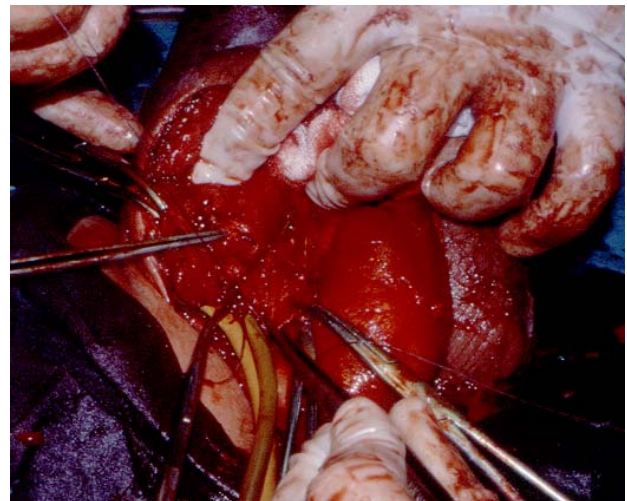


Fig. 3 – The site of rupture of *tunica albuginea*. Evacuation of hematoma reveals transversal *t. albuginea* laceration of the right *corpus cavernosum*, spreading from 10–11 hours to 6 hours, not extending to the left *corpus cavernosum*. The rupture has well-defined edges like knife incision.

In one year follow-up the patient presented with normal erectile and voiding function.

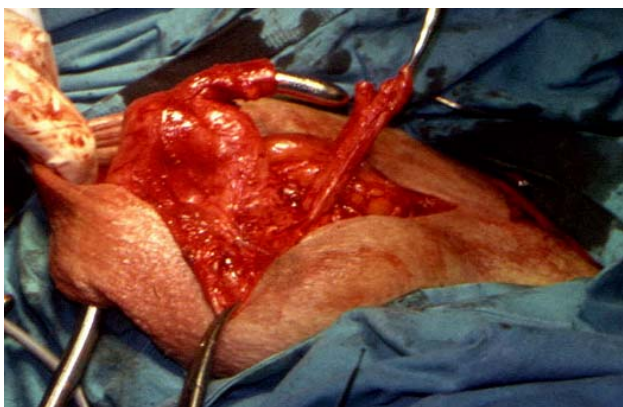


Fig. 4 – Complete rupture of the penile urethra. The distal end of urethra with refreshed margins, resected remnants are found on Bénéiqué. The proximal part of the urethra elevated by the forceps. Note the edges of the urethra – worn-out with fringes.

Discussion

Adequate management of penile fracture in view of surgical or conservative treatment has been the issue of controversy⁷. Randomized prospective studies on conservative treatment of penile fractures reported significant immediate and late complications. The frequency of complications of conservative treatment is between 10% and 53%^{8, 9}. Conservative (nonsurgical) treatment may cause complications, such as penile curvature, pain during erection, fibrotic penile lesions, arteriovenous fistula, infection, and erectile dysfunction curvature of the penis, erectile dysfunction^{9, 10}.

Currently, early surgical treatment is believed to yield excellent results, short hospitalization, low morbidity and early restoration to normal sexual activity^{3, 9, 10}.

Vigorous sexual intercourse was the cause of penile fracture with complete urethral rupture in this case report. Transversal tear of *t. albuginea* was noted in operated patient, in relation to longitudinal axis of the penis. During erection, there is a five-fold reduction of *t. albuginea* thickness. It is very vulnerable to traumatic rupture²⁻⁴. Also, the tunica of the erect penis, the firmly engorged *corpora cavernosa* under strain of buckling can generate pressures in excess of 1500 mmHg and exceed the limit of the thinned tunica⁹.

Urethral rupture is associated in up to 38% of penile fracture due to high energy trauma^{6, 10}. Voiding difficulties, hematuria and blood at the meatus are usual signs of urethral injury, but the absence of these features does not exclude the possibility of urethral injury¹⁰. Evidence of bilateral corporal rupture should also be prompt investigation for a potential urethral injury, because bilateral corporal rupture have a higher of urethral disruption compared with unilateral fractures^{9, 10}. Based on the available literature, urethral rupture is usually partial, rarely complete.

Conclusion

Fracture of the penis is relatively uncommon and is considered as urologic emergency. Prompt surgical exploration and repair can preserve erectile and voiding function.

Concomitant complete urethral rupture is rare, but it is almost always associated with bilateral corporeal injury. However, complete rupture of the urethra may be associated with rupture of one corpus cavernous only.

REFERENCES

1. Mellinger BC. Blunt traumatic injuries of the penis. In: Hashmat AI, Das S, editors. The Penis. Philadelphia: Zea & Febiger; 1993. p. 105–13.
2. Yapanoglu T, Aksoy Y, Adanur S, Kabadayi B, Ozturk G, Ozbey I. Seventeen years' experience of penile fracture: conservative vs. surgical treatment. J Sex Med 2009; 6(7): 2058–63.
3. Ibrahim-Housseiny I, Tholoth HS, Mohsen T, Hekal LA, Assmy A. Penile fracture: long-term outcome of immediate surgical intervention. Urology 2010; 75(1): 108–11.
4. Brock G, Hsu GL, Nunes L, von Heyden B, Lue TF. The anatomy of the tunica albuginea in the normal penis and Peyronie's disease. J Urol 1997; 157(1): 76–81.
5. Zargooshi J. Penile fracture in Kermanshah, Iran: Report of 172 cases. J Urol 2000; 164(2): 364–6.
6. Eke N. Fracture of the penis. Br J Surg 2002; 89(5): 555–65.
7. Gamal WM, Osman MM, Hammady A, Aldabshoury ZM, Hussein MM, Saleem M. Penile fracture: long-term results of surgical and conservative management. J Trauma 2011; 71(2): 491–3.
8. Cavalcanti AG, Krambeck R, Araiho A, Rabelo PH, Carvalho JP, Favorito LA. Management of urethral lesions in penile blunt trauma. Int J Urol 2006; 13(9): 1218–20.
9. Jack GS, Garraway I, Reznicek R, Rajfer J. Current treatment options for penile fractures. Rev Urol 2004; 6(3): 114–20.
10. Yamaçake KG, Tavares A, Padovani GP, Guglielmetti GB, Cury J, Srougi M. Long-term Treatment Outcomes Between Surgical Correction and Conservative Management for Penile Fracture: Retrospective Analysis. Korean J Urol 2013; 54(7): 472–6.

Received on August 9, 2013.

Revised on September 9, 2013.

Accepted on November 22, 2013.